

NOTE

Cushing's disease due to double pituitary ACTH-secreting adenomas: the first case report

Massimiliano Andrioli¹, Francesca Pecori Giraldi¹, Marco Losa², Mariarosa Terreni³, Cecilia Invitti⁴ and Francesco Cavagnini¹

¹Chair of Endocrinology, University of Milan, IRCCS Ospedale San Luca, Istituto Auxologico Italiano, Milan, Italy

²Pituitary Unit, Department of Neurosurgery, San Raffaele Scientific Institute, Vita-Salute University, Milan, Italy

³Pathology Unit, San Raffaele Scientific Institute, Vita-Salute University, Milan, Italy

⁴Department of Medical Sciences and Rehabilitation, IRCCS Ospedale San Michele, Istituto Auxologico Italiano, Milan, Italy

Abstract. Double pituitary adenomas are rare occurrences in autopsical, surgical and neuroradiological series and are mostly due to non-functioning pituitary adenomas, GH-secreting and prolactin-secreting adenomas. ACTH secreting tumours are more rare and, to our knowledge, two distinct ACTH-producing adenomas within the same pituitary have never been reported. We herewith describe a 56 year old woman with Cushing's disease due to two clearly distinct ACTH-secreting pituitary adenomas. She presented with signs and symptoms of hypercortisolism and hormonal testing was indicative for pituitary-dependent Cushing's syndrome. Sellar MRI visualized an asymmetric pituitary gland with suspect lesions in both the right and the left pituitary lobes. Both lesions were removed during transsphenoidal surgery and remission of hypercortisolism ensued. Pathology confirmed the existence of two distinct adenomas located in different sites in the gland. Both presented ACTH immunoreactivity but displayed distinct morphological features. Our case indicates that double ACTH-secreting pituitary adenomas may occur in patients with Cushing's disease. Careful radiological, surgical and pathological examination is necessary to recognize this condition and avoid surgical failure.

Key words: Pituitary, Double adenomas, Cushing's disease, ACTH

MULTIPLE pituitary adenomas are rare occurrences, as the reported prevalence among autopsy and surgical series is less than 1% [1-5]. Multiple adenomas may also be detected prior to surgery, thanks to the increasing sensitivity of modern neuroradiological techniques [3, 6].

A variety of tumour combinations have been reported, with the three most common pituitary tumours, *i.e.*, non-functioning pituitary adenomas, GH-secreting and prolactin-secreting adenomas, making up the lion's share [2-12]. ACTH-secreting tumours are more rare, both as single and multiple tumours [13], and, to our knowledge, two ACTH-producing adenomas within the same pituitary have never previously been reported.

We describe the first case of Cushing's disease due to two clearly distinct ACTH-secreting pituitary adenomas.

Case report

A 56 year-old woman came to our attention with signs and symptoms of hypercortisolism, *i.e.* weight gain with central fat distribution, hypertension, hypokalemia. Endocrine investigation showed ACTH-dependent hypercortisolism, and dynamic testing (CRH stimulation, 8 mg dexamethasone suppression) was indicative for pituitary ACTH hypersecretion (Table 1). Sellar MRI visualized an asymmetric pituitary gland with a contrast-enhanced microadenoma on the left side and an inhomogeneous area on the right (Fig. 1).

Transsphenoidal adenomectomy was advised and careful surgical exploration allowed the removal of two clearly distinct lesions: one in the left lobe, paramedian and close to the neurohypophysis (sample 1)

Received May 7, 2010; Accepted Jun. 14, 2010 as K10E-140
Released online in J-STAGE as advance publication Jun.26, 2010

Correspondence to: Prof. Francesco Cavagnini, Chair of Endocrinology, University of Milan, IRCCS Ospedale San Luca, Istituto Auxologico Italiano, Via Spagnoletto 3, 20149 Milan, Italy.
E-mail: cavagnini@auxologico.it

Table 1 Biochemical parameters in the active phase and after surgical remission

	Active phase	After surgery	Reference range
Urinary free cortisol ($\mu\text{g}/24\text{h}$)	228	10	20-80
Serum cortisol diurnal variation ($\mu\text{g}/\text{dL}$)	(8AM)	17.8	1
	(24PM)	14.1	0.9
Serum cortisol after 1 mg dexamethasone ($\mu\text{g}/\text{dL}$)	3.5	1.1	<1.8
Serum cortisol after 8 mg dexamethasone ($\mu\text{g}/\text{dL}$)	3.2 (81% decrease)	--	decrease by at least 50% indicative of Cushing's disease
Plasma ACTH (pg/mL)	89	6	10-50
CRH test			
ACTH: baseline – peak	62 – 113 (82% increase)	--	increase by at least 35% indicative of Cushing's disease
cortisol: baseline – peak	17 – 21 (21% increase)	--	increase by at least 20% indicative of Cushing's disease
Serum potassium (mmol/L)	3.3	3.9	3.5-5.4

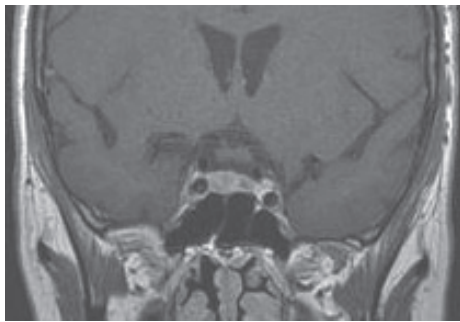


Fig. 1 Coronal pituitary MRI after gadolinium showing an asymmetric pituitary gland with a contrast-enhanced microadenoma on the left and an inhomogeneous area on the right side of the gland.

and the other in the right pituitary lobe (sample 2). Successful removal of the ACTH-secreting tumour was confirmed by postsurgical hypoadrenalism (Table 1), accompanied by clinical manifestations of adrenal insufficiency which required steroid replacement therapy for 10 months. Two years after surgery, the patient remains in remission.

Methods

Four micron sections were cut from paraffin blocks of both pituitary samples fixed in 10% buffered formalin and stained with haematoxylin and eosin (H&E), PAS and Gomori. Immunohistochemical investigation was carried out for ACTH (anti-ACTH antibody from Novo Castra, Newcastle, UK 1:1500), GH (antibody from Novo Castra, Newcastle, UK, 1:5000), prolactin (antibody from Immunotech, Marseille, France,

1:200), FSH (antibody from Immunotech, Marseille, France, 1:6000), LH (antibody from Immunotech, Marseille, France, 1:4000) and TSH (antibody from Immunotech, Marseille, France, 1:3200).

Pathology

Examination of pituitary specimens by light microscopy showed two distinct adenomas: a 2-mm microadenoma close to the neurohypophysis in sample 1 (adenoma 1, Fig. 2A) and a 9-mm microadenoma in the right side of the pituitary in sample 2 (adenoma 2, Fig. 3A). The two adenomas presented distinct morphological features. Adenoma 1, located in transitional area between adeno- and neurohypophysis, was characterized by blurred margins, small cells with peripheral nuclei and highly basophilic cytoplasm; it also contained sparse haemorrhagic areas (Fig. 2B). Conversely, adenoma 2 was well demarcated from surrounding adenohypophysis by a thin fibrous capsule and made of larger, weakly basophilic cells (Fig. 3B). Both adenomas were intensely positive for ACTH, with adenoma 1 exhibiting stronger staining than adenoma 2 (Figs. 2C and 3C), and negative for GH, PRL, TSH, FSH and LH. The remaining surgical specimens presented normal pituitary morphology. These distinct locations and morphological features argue against a single, horse-shoe adenoma.

Discussion

Double pituitary adenomas are defined as simultaneous, morphologically or immunocytologically dis-

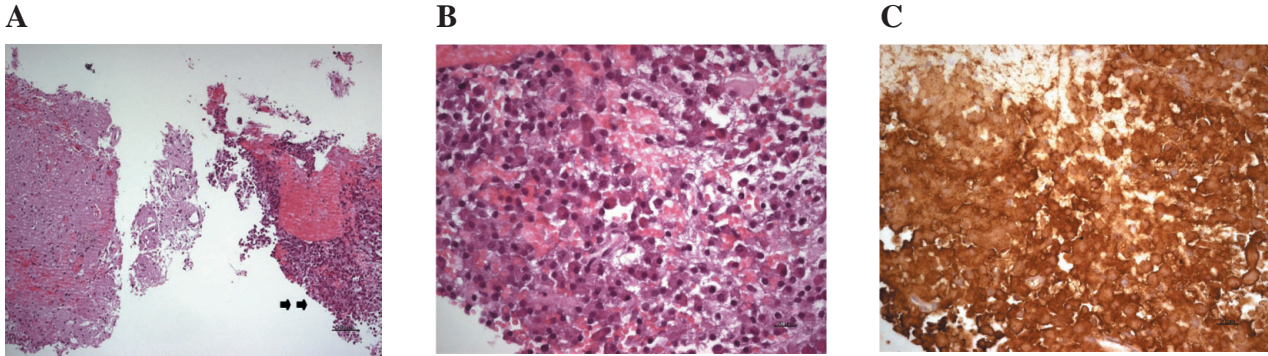


Fig. 2 (A) Microadenoma, composed of small basophilic cells (arrows to right) with blurred margins and close to the neurohypophysis (left). (H&E, 10x), (B) Microadenoma, characterized by small, intensely basophilic cells with sparse signs of haemorrhagia. (H&E, 40x), (C) Adenomatous cells with positive immunohistochemistry for ACTH. (IHC, 20x)

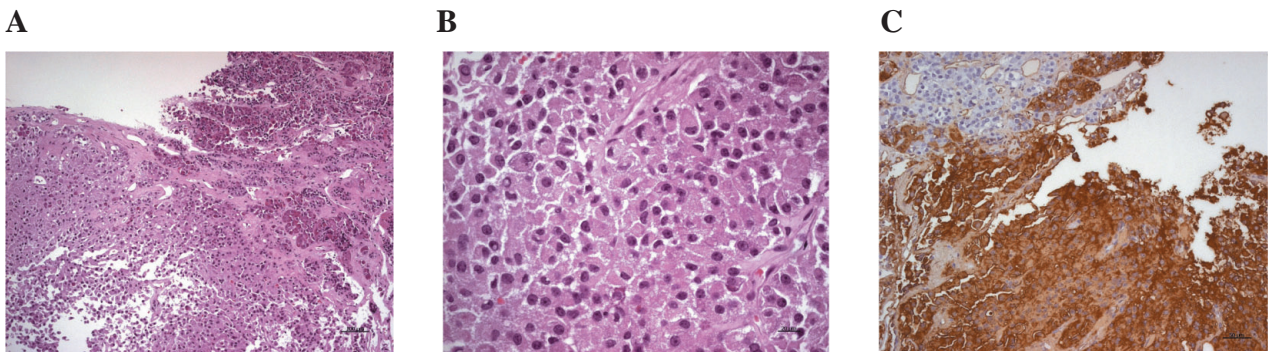


Fig. 3 (A) Fibrous capsule surrounding a well-circumscribed adenoma in the adenohypophysis. Adenomatous cells with abundant basophilic cytoplasm. (H&E, 10x), (B) Solid adenoma characterized by medium-large basophilic cells with peripheral nuclei. (H&E, 40x), (C) Adenomatous cells with positive immunostaining for ACTH; (IHC, 20x)

tinct tumours in the pituitary. They are classified as *clearly separated double tumours*, visible at preoperative imaging or during surgical exploration, and *contiguous double tumours* which are too close to be easily distinguished as separate tumours before surgery and are often removed as a single lesion with the pathologist providing the final diagnosis. Of note, double pituitary adenomas should be distinguished from composite, plurihormonal pituitary adenomas as the latter feature a single pituitary lesion with diverse immunohistochemical reactivity [14]. Indeed, multiple hormonal staining at immunohistochemistry is not infrequent.

Conversely, the reported prevalence of double pituitary adenomas is quite low, ranging from 0.004–0.01% in surgical series [2, 3, 5, 13] to 0.05–0.9% in autopsy series [1, 4]. The higher detection rate in postmortem series might reflect the difficulty in identifying these small tumours during surgery, their possible loss by suction and surgical manipulations, and the fragmen-

tation of specimens sent to the pathologist. However, the clinical importance of detecting all pituitary lesions is readily apparent as failure to detect and remove a hormone-secreting adenoma may lead to poor surgical outcome if the noncausative lesion was removed [15, 16]. Indeed, absent pathological confirmation of tumour resection is considered, by some, a criterion for immediate repeat transsphenoidal surgery in patients with Cushing's disease [15] although not all agree [17, 18].

ACTH-secreting pituitary adenomas account for a small share of pituitary tumors and are similarly rare as second tumours [2, 5, 13, 19]; indeed, the majority of double adenomas feature GH- or prolactin-secreting or non-functioning adenomas [2, 3, 5, 7, 8, 20]. ACTH-secreting pituitary adenomas have been described together with FSH-secreting lesions [21], GH-secreting [13] and, most commonly, with prolactin-secreting adenomas [2, 13, 19, 22–24] or silent prolactin-immunoreactive adenomas [19, 25].

To our knowledge, a case with two pathologically well-characterized, distinct ACTH-secreting adenomas within the same pituitary have never previously been documented in the English literature and our patient probably represents the first report of Cushing's disease due to double ACTH-secreting pituitary adenomas. Of note, in an extensive review of over 660 pituitary specimens removed from patients with Cushing's disease, none presented two ACTH-secreting lesions [13]. A suspicion as to the possibility of multiple pituitary lesions already arose with MRI which revealed lesions in both pituitary lobes. Indeed, advances in neuroradiological techniques have led to an increased awareness of multiple pituitary adenomas [3, 6] and encouraged the surgeon to perform a thorough pituitary exploration. However, it is worth recalling that ACTH-secreting adenomas are usually small and often escape neuroradiological detection [26] even with the most advanced equipment [27], or yield equivocal findings such as "inhomogeneous area" [28], thus extensive surgical exploration is commonly performed. In our patient, imaging guided the surgeon to accurately explore both pituitary lobes and led to the removal of two distinct pituitary adenomas, one close to the neurohypophysis and the other square in the right pituitary lobe. The different morphological features of the two adenomas *e.g.*, differently sized cells, variable basophilism and cytoplasm appearance, concurred with surgical report, indeed proved crucial as both tumors stained for ACTH thus distinction based on immunohistochemistry alone could not be performed. Pathological and surgical findings also allowed to exclude "false" double adenomas which may

occur if the tumor presents hourglass or horseshoe form and the surgeon fails to remove the entire lesion.

Careful surgical and pathological exploration are necessary not only to correctly identify double pituitary adenomas but also essential to avoid missing the causative adenomas and risking surgical failure. Indeed, failure to remove the ACTH-secreting lesion is the most frequent cause of persistent hypercortisolism [16] and the coexistence of multiple adenomas within the same pituitary gland has been suggested as a cause of surgical failure [29]. There have indeed been reports of patients with Cushing's disease in whom initial surgery led to the removal of prolactin- or GH-secreting tumors and the causative ACTH-secreting tumour was removed only at repeat surgery [13, 22]. In these cases, the failure to stain for ACTH in the initially removed specimens and persistence of hypercortisolism, encouraged the surgeon to re-attempt pituitary adenectomy. Conversely, surgical failure after removal of an ACTH-positive adenoma, an infrequent but not so rare occurrence [26], does not lend itself to simple solutions. In our case, had the surgeon failed to remove both ACTH-secreting adenomas then hypercortisolism would have likely persisted and the patient classified as surgical failure notwithstanding the removal of a causative lesion.

In conclusion, double pituitary ACTH-secreting adenomas may occur in patients with Cushing's disease and could complicate surgical management. If pituitary imaging is suspicious for multiple lesions then surgical exploration has to be thorough in order to avoid surgical failures.

References

1. Kontogeorgos G, Kovacs K, Horvath E, Scheithauer BW (1991) Multiple adenomas of the human pituitary. A retrospective autopsy study with clinical implications. *J Neurosurg* 74: 243-247.
2. Kontogeorgos G, Scheithauer BW, Horvath E, Kovacs K, Lloyd R, Smyth HS, Rologis D (1992) Double adenomas of the pituitary: a clinicopathological study of 11 tumors. *Neurosurgery* 31: 840-849.
3. Kim K, Yamada S, Usui M, Sano T (2004) Preoperative identification of clearly separated double pituitary adenomas. *Clin Endocrinol (Oxf)* 61: 26-30.
4. Buurman H, Saeger W (2006) Subclinical adenomas in postmortem pituitaries: classification and correlations to clinical data. *Eur J Endocrinol* 154: 753-758.
5. Sano T, Horiguchi H, Xu B, Li C, Hino A, Sakaki M, Kannuki S, Yamada S (1999) Double pituitary adenomas: six surgical cases. *Pituitary* 1: 243-250.
6. Cannavò S, Curtò L, Lania A, Saccomanno K, Salpietro FM, Trimarchi F (1999) Unusual MRI finding of multiple adenomas in the pituitary gland: a case report and review of the literature. *Magn Reson Imaging* 17: 633-636.
7. Syro LV, Horvath E, Kovacs K (2000) Double adenoma of the pituitary: a somatotroph adenoma colliding with a gonadotroph adenoma. *J Endocrinol Invest* 23: 37-41.

8. Kannuki S, Matsumoto K, Sano T, Shintani Y, Bando H, Saito S (1996) Double pituitary adenoma-two case reports. *Neurol Med Chir* 36: 818-821.
9. Shimizu C, Koike T, Sawamura Y (2004) Double pituitary adenomas with distinct histological features and immunophenotypes. *J Neurol Neurosurg Psychiatry* 75: 140.
10. Yamada S, Yoshimoto K, Sano T, Takada K, Itakura M, Usui M, Teramoto A (1997) Inactivation of the tumor suppressor gene on 11q13 in brothers with familial acro-gigantism without multiple endocrine neoplasia type 1. *J Clin Endocrinol Metab* 82: 239-242.
11. Shintani Y, Yoshimoto K, Horie H, Sano T, Kanesaki Y, Hosoi E, Yokogoshi Y, Bando H, Iwahana H, Kannuki S (1995) Two different pituitary adenomas in a patient with multiple endocrine neoplasia type 1 associated with growth hormone-releasing hormone-producing pancreatic tumor: clinical and genetic features. *Endocr J* 42: 331-340.
12. Tolis G, Bertrand G, Carpenter S, McKenzie JM (1978). Acromegaly and galactorrhea-amenorrhea with two pituitary adenomas secreting growth hormone or prolactin. A case report. *Ann Intern Med* 89: 345-348.
13. Ratliff JK, Oldfield EH (2000) Multiple pituitary adenomas in Cushing's disease. *J Neurosurg* 93: 753-761.
14. Scheithauer BW, Horvath E, Kovacs K, Laws ER Jr, Randall RV, Ryan N (1986) Plurihormonal pituitary adenomas. *Semin Diagn Pathol* 3: 69-82.
15. Locatelli M, Vance ML, Laws ER (2005) Clinical review: the strategy of immediate reoperation for transsphenoidal surgery for Cushing's disease. *J Clin Endocrinol Metab* 90: 5478-5482.
16. Pouratian N, Prevedello DM, Jagannathan J, Lopes MB, Vance ML, Laws ER Jr (2007) Outcomes and management of patients with Cushing's disease without pathological confirmation of tumor resection after transsphenoidal surgery. *J Clin Endocrinol Metab* 92: 3383-3388.
17. Cavagnini F, Pecori Giraldi F (2008) Transsphenoidal surgery for Cushing's disease-importance of histopathology for prediction of outcome. *Nat Clin Pract Endoc Metab* 4: 14-15.
18. Biller BM, Grossman AB, Stewart PM, Melmed S, Bertagna X, Bertherat J, Buchfelder M, Colao A, Hermus AR, Hofland LJ, Klibanski A, Lacroix A, Lindsay JR, Newell-Price J, Nieman LK, Petersenn S, Sonino N, Stalla GK, Swearingen B, Vance ML, Wass JA, Boscaro M (2008) Treatment of adrenocorticotropin-dependent Cushing's syndrome: a consensus statement. *J Clin Endocrinol Metab* 93: 2454-2462.
19. Meij BP, Lopes MB, Vance ML, Thorner MO, Laws ER (2000) Double pituitary lesions in three patients with Cushing's disease. *Pituitary* 3: 159-168.
20. Blevins LS Jr, Hall GS, Madoff DH, Laws ER Jr, Wand GS (1992) Case report: acromegaly and Cushing's disease in a patient with synchronous pituitary adenomas. *Am J Med Sci* 304: 294-297.
21. Oyama K, Yamada S, Hukuhara N, Hiramatsu R, Taguchi M, Yazawa M, Matsuda A, Ohmura E, Imai Y (2006) FSH-producing macroadenoma associated in a patient with Cushing's disease. *Neuro Endocrinol Lett* 27: 733-736.
22. McKelvie PA, McNeill P (2002) Double pituitary adenomas: a series of three patients. *Pathology* 34: 57-60.
23. Wynne AG, Scheithauer BW, Young WF Jr, Kovacs K, Ebersold MJ, Horvath E (1992). Coexisting corticotroph and lactotroph adenomas: case report with reference to the relationship of corticotropin and prolactin excess. *Neurosurgery* 30: 919-923.
24. Jastania RA, Alsaad KO, Al-Shraim M, Kovacs K, Asa SL (2005). Double adenomas of the pituitary: transcription factors Pit-1, T-pit, and SF-1 identify cytodifferentiation and differentiation. *Endocr Pathol* 16: 187-194.
25. Pantelia E, Kontogeorgos G, Piaditis G, Rologis D (1998) Triple pituitary adenoma in Cushing's disease: case report. *Acta Neurochir* 140: 190-193.
26. Invitti C, Pecori Giraldi F, De Martin M, Cavagnini F (1999) Diagnosis and management of Cushing's syndrome: results of an Italian multicentre study. *J Clin Endocrinol Metab* 84: 440-448.
27. Ikeda H, Abe T, Watanabe K (2010) Usefulness of composite methionine-positron emission tomography/3.0-tesla magnetic resonance imaging to detect the localization and extent of early-stage Cushing adenoma. *J Neurosurg* 112: 750-755.
28. Mampalam TJ, Tyrrell JB, Wilson CB (1988) Transsphenoidal microsurgery for Cushing disease. A report of 216 cases. *Ann Intern Med* 109: 487-493.
29. Woosley RE (1983) Multiple secreting microadenomas as a possible cause of selective transsphenoidal adenectomy failure. *Case report. J Neurosurgery* 58:267-269.